

The role of bronchoalveolar lavage in interstitial lung disease

Keith C. Meyer, MD

*Department of Medicine, University of Wisconsin Medical School, K4/930 Clinical Sciences Center,
600 Highland Avenue, Madison, WI 53792-9988, USA*

Considerable progress has been made during the past 10 years in understanding the clinicopathologic similarities and differences among the various acute and chronic forms of diffuse parenchymal lung disease, collectively referred to as interstitial lung diseases (ILDs). This is true particularly for the different forms of idiopathic interstitial pneumonia (IIP), which are now recognized as distinct clinicopathologic entities that vary in their clinical characteristics and their prognosis [1–3]. Lung parenchymal evaluation by high-resolution CT scanning (HRCT) of the chest has evolved to the point that it may provide images that are virtually diagnostic of certain forms of ILD [4–6], but other testing, including bronchoalveolar lavage (BAL) and lung biopsy, may be required to secure an accurate diagnosis. The differential diagnosis of these disorders rests on the clinician's interpretation of the patient's clinical presentation combined with physical examination findings, pulmonary function testing, radiographic imaging, and, if required, sampling of lung tissue. This discussion examines the usefulness of BAL in the diagnosis of specific forms of ILD.

Bronchial irrigation with saline solution was reported first by Stitt in 1927 [7], who introduced the term, "bronchial lavage," in 1932 [8]. Lavage of more distal areas of the lung was reported as a therapy for septic lung disease and pulmonary alveolar proteinosis 4 decades later [9,10], and it also was used to study lower respiratory tract immunity in various animal models in the 1960s [11–14].

Reynolds and Newball introduced saline lavage of a portion of the lung via the flexible bronchoscope as a research tool in 1974 [15], and saline lavage of a defined area of the lung became known as BAL. Hundreds of articles on BAL as a research and a diagnostic tool appeared in the literature in the 1980s and 1990s, as clinical use of the flexible fiberoptic bronchoscope exploded. Although the technique rapidly gained acceptance as a means of retrieving cells and proteins from the lower respiratory tract for diagnostic purposes, various centers used their own, often unique, techniques for performing lavage. Because the techniques used could affect results obtained from BAL fluid analysis, eventually attempts were made to standardize BAL methods. The European Respiratory Society published recommendations that addressed the technical aspects of performing BAL [16,17], and four centers in the United States performed standardized studies and published specific recommendations for the performance and analysis of BAL [18]. Nonetheless, the techniques for performance and analysis of BAL never have been standardized to the point where a uniform technique is used by all pulmonologists and analytic laboratories.

The role of radiographic imaging and invasive procedures in the diagnosis of interstitial lung diseases

HRCT of the chest has revolutionized the clinician's ability to noninvasively image the lung and detect imaging patterns highly suggestive of a

E-mail address: kcm@medicine.wisc.edu

specific diagnosis [4–6]. Along with the widespread clinical application of HRCT, the understanding of ILD, especially the different forms of IIP, has evolved greatly from a histopathologic standpoint [1–3]. Forms of IIP can now be differentiated by their specific clinicopathologic characteristics and their HRCT correlates (Table 1). For the most part, these IIP entities previously were undifferentiated and termed idiopathic pulmonary fibrosis (IPF) or cryptogenic fibrosing alveolitis and believed to be variations of a single pathologic process. IPF, however, now refers specifically to the most common form of IIP that shows a usual interstitial pneumonitis (UIP) pattern on histopathologic examination of lung tissue in the absence of rheumatologic disease.

In some instances, HRCT patterns are virtually diagnostic of some forms of ILD, but additional diagnostic testing may be required to firm up a diagnosis and exclude other possible disorders. BAL provides a safe and generally well-tolerated means of retrieving secretions that coat the surfaces of bronchial and alveolar epithelium, although these secretions are diluted considerably by the saline used to perform BAL, and technical factors can affect the cellular and acellular profile of the retrieved bronchoalveolar epithelial surface fluid. During the past 3 decades, when BAL has been applied to the clinical evaluation of patients who have had various forms of lung disease, its diagnostic potential for ILD has been hampered by a lack of specificity. Nonetheless, certain patterns in differential cell count correlate well with certain forms of ILD, such as sarcoidosis. Transbronchial lung biopsy, although frequently diagnostic of certain forms of ILD, also has its limitations; tissue sampling may be inadequate and nondiagnostic, and the risk of a complication, although low, is increased compared with use of

bronchoscopy with BAL only [19,20]. Surgical lung biopsy allows sampling of lung tissue that nearly always is diagnostic, but the risk of complications, including death, is not negligible [21,22]. BAL can provide a safe and useful tool for the diagnosis of ILD when combined with aspects of the clinical presentation and HRCT scanning.

Clinical use of bronchoalveolar lavage

Bronchoscopy with BAL has a low complication rate, but it can be associated with significant complications [23]. Each patient should have a thorough evaluation before the procedure, including a medical history, focused physical examination, and pulmonary function testing. Coagulation studies, including platelet count, prothrombin time, and partial thromboplastin time, are recommended, especially if any biopsy procedure is performed. Intravenous access should be established if conscious sedation is employed, and minimal doses of topical anesthetic are given to achieve patient comfort and cough control. During the procedure, heart rate and oxyhemoglobin saturation should be monitored. Fever, chills, and extreme malaise (postbronchoscopy fever) may occur within hours after BAL as a result of proinflammatory mediator release [24], which can occur occasionally and seems linked to larger volumes of instilled fluid. Warming of normal saline aliquots used for lavage to 37°C before instillation during the BAL procedure may help reduce cough.

Bronchoalveolar lavage technique

The most important objective when performing BAL is to have adequate amounts of instilled saline

Table 1
Clinicopathologic classification of the idiopathic interstitial pneumonias

Clinical diagnostic entity	Histopathologic pattern	Acronym
Idiopathic pulmonary fibrosis ^{a,b}	Usual interstitial pneumonitis ^c	IPF ^a /UIP ^c
Nonspecific interstitial pneumonia	Nonspecific interstitial pneumonia	NSIP
Cryptogenic organizing pneumonia ^d	Organizing pneumonia	COP
Desquamative interstitial pneumonia	Desquamative interstitial pneumonia	DIP
Respiratory bronchiolitis interstitial lung disease	Respiratory bronchiolitis	RBILD
Acute interstitial pneumonia	Diffuse alveolar damage	AIP
Lymphoid interstitial pneumonia	Lymphoid interstitial pneumonia	LIP

^a Term used to describe clinical entity.

^b Alternate term, cryptogenic fibrosing alveolitis.

^c Term used by pathologists and radiologists.

^d Alternate term, bronchiolitis obliterans with organizing pneumonia.

reach the pathologic areas that are involved by the inflammatory or infectious process so that the retrieved BAL fluid reflects changes in cells and solutes caused by the disease process. Technical aspects of BAL can affect the adequacy of bronchoalveolar secretion retrieval. Although the European Respiratory Society has published guidelines to reduce the variability of BAL analytic results [16,17], variability in the way that BAL is performed and in BAL analysis persist. Use of a centralized laboratory can be helpful and reduce variability in BAL processing and analysis [25]. Typically, the right middle lobe or the lingula is chosen as a site for lavage when diffuse disease is present. These sites are entered easily with the bronchoscope, and the distal end of the bronchoscope can be wedged in segmental bronchi in these areas to isolate the segment targeted for lavage from the rest of the tracheobronchial tree. Fluid retrieval tends to be good from these areas. The HRCT, however, can be used to choose the anatomic area or areas of the lung for BAL. Occasionally, some areas of the lung may have little change on HRCT, whereas others seem to be involved prominently; areas with HRCT abnormalities should be subjected to lavage if such involvement is not seen in the right middle lobe or lingula.

Many factors can affect the efficacy of sampling bronchoalveolar secretions, and inadequate technique may corrupt the ability of BAL to reflect changes in cells and acellular components of epithelial surface liquid that occur when the lung is inflamed. These factors include airway collapse, the amount of saline instilled, volume that is retrieved for analysis, and positioning of the patient. Loss of airway support, as occurs in emphysema, may lead to airway collapse even when minimal amounts of negative pressure are applied. If airways collapse despite minimal negative pressure and instilled lavage fluid cannot be retrieved in patients who have emphysema, the distal end of the bronchoscope may have to be withdrawn slightly to break the wedge position and allow passive return of lavage fluid that is immediately suctioned into a reservoir if less than 5% to 10% of the instilled fluid can be aspirated from the wedge position. Keeping the amount of negative pressure to a minimal level that allows retrieval of fluid prevents airway collapse unless advanced emphysema is present, and many bronchoscopists prefer to use multiple saline aliquots that are instilled and aspirated sequentially via a hand-held syringe while observing the airways for collapse as lavage fluid is drawn back into the syringe. Wall suction, if used to generate negative suction pressure, should be used with great caution and kept at a low value (eg, <25–100 mm Hg).

Positioning the patient so that the areas to be lavaged are not in a gravity-dependent position also facilitates retrieval of BAL fluid. If a minimal amount of saline is instilled, especially if the volume is less than 40 to 50 mL, sampling of airspace secretions largely reflects proximal airway surfaces and not more distal bronchoalveolar surfaces that are of interest in patients who have diffuse interstitial infiltrates. Multiple aliquots of saline with total volumes ranging from 100 to 200 mL and retrieval of at least 5% to 10% of the instilled fluid likely provides a reasonable sampling for cellular analysis and other studies that can contribute meaningfully to a diagnosis of specific ILD. Smaller volumes of instilled fluid are unlikely to provide a lavage that truly can be considered an adequate bronchoalveolar sample. Instilled total volumes of saline, ranging from 100 mL to 250 mL, however, seem to give similar cell differentials in patients who have ILD [26,27].

Processing of bronchoalveolar fluid

Subsequent handling of BAL fluid also may affect the accuracy of its analysis. Fluid retrieved from the first instilled aliquot has a low cell count compared with subsequent retrieved aliquots, and some investigators suggest discarding this first aliquot because it reflects mostly large, proximal airway secretions [28]. There are no data, however, to indicate that this aliquot should not be pooled with subsequent aliquots. Aspirated fluid also may contain tenacious mucus, and some groups filter BAL through loose gauze before subsequent analysis. Cells may adhere to mucus and affect the cell profile of the BAL if it is strained through gauze, however. Some laboratories use dithiothreitol (Sputolysin) to disperse the mucus and minimize its effect on BAL cellular components. Lavage fluid should not be placed in plasticware or other containers that promote cell adherence, which is likely to affect total and differential cell counts significantly.

Ideally, BAL fluid should be processed quickly. It can be kept at 4°C, however, for long periods (up to 24 hours) with little effect on cell count and differential. Because saline is nutrient poor and cell viability becomes an issue with prolonged storage, some investigators add small amounts of cell culture medium to maintain cell viability. The total cell count (nucleated leukocytes) should be obtained and preferably is performed on an unconcentrated aliquot of pooled BAL fluid. Some laboratories centrifuge and concentrate BAL cellular components before performing a total cell count, however. Vigorous

agitation should be avoided if cell pellets are re-suspended in media after centrifugation. The concentration of erythrocytes and epithelial cells also should be noted, and cell viability should be determined by incorporating Trypan Blue into the counting fluids. Uncentrifuged BAL fluid should be used for bacterial and viral cultures if these are needed to rule out infection [29], although centrifugation may enhance the detection of viruses via microscopic examination of stained specimens or via assays that detect viral nucleic acids. Centrifuged BAL specimens can be used to optimize culture for mycobacteria, fungi, Legionella, Mycoplasma, and Chlamydiae. Multiple cytospin preparations should be made for staining with Giemsa-Wright or May-Grünwald-Giemsa to determine nucleated white blood cell (WBC) differential counts. A standardized protocol for cyto-centrifugation should be used uniformly, because various factors, including centrifuge speed, the area of the slide on which the cells are deposited, and the number of cells counted, can influence the results of cell counts [30]. Additional staining (Gram's, toluidine blue O, Gomori methenamine silver, Ziehl-Neelsen, or Papanicolaou's) to identify bacteria, Pneumocystis carinii, mycobacteria, fungi, or malignant cells should be performed on cytospin preparations if indicated clinically.

Analysis of bronchoalveolar lavage cellular components

Adequate numbers of cells must be examined to obtain an accurate, statistically meaningful representation of cell populations that account for a small percentage of the total BAL nucleated WBCs. At least 300 cells should be examined randomly on a single slide, and averaging the differential cell count of two different cytospin slides likely increases accuracy. In addition to WBCs, the presence of microorganisms, red cells, epithelial cells, and atypical/malignant cells should be sought and recorded.

Diffuse infiltration of the lung by lymphangitic carcinomatosis or primary bronchoalveolar carcinoma can be diagnosed via cytopathology in up to 90% of cases [31–33]. Additional cytospin slides should be reserved for specialized staining as needed. In some instances, it may be desirable to determine lymphocyte subsets via antibodies directed against CD4 and CD8 antigens, or, if Langerhans' histiocytosis of lung is suspected, anti-CD1a. If hematopoietic infiltrative neoplasm is suspected, specific antibodies combined with flow cytometry can identify monoclonal lymphocyte populations.

Many studies have examined BAL cell profiles in healthy volunteers to compare how these are altered in various disease states. Many of these studies, however, show some degree of variation in cell concentrations and differential cell count, and low numbers of normal subjects were included. Furthermore, smoking can affect the BAL cell profile, and some studies have included smokers and nonsmokers in the healthy volunteer group. The BAL Cooperative Study (Table 2), however, examined a large number of normal volunteers subjected to lavage with a uniform protocol of four sequential 60-mL aliquots of normal saline, and this study included smoking, ex-smoking, and never-smoking healthy individuals [18]. It did not examine age as a possible variable, however, which may affect BAL cell profiles. Mild alterations in cell concentrations and differential cell counts may be seen in older healthy patients [34]. Nonetheless, the BAL Cooperative study showed that in normal, nonsmoking individuals, the differential cell count should show macrophages to represent at least 80% to 85% of nucleated WBCs and lymphocytes 5% to 20% of nucleated WBCs. Granulocytes should be present in low numbers, with neutrophils less than 2% to 3% and eosinophils less than 1%. Smoking tends to increase the number of macrophages per milliliter of BAL fluid [18,35]. It also increases neutrophils per milliliter and may increase the percentage of neutrophils on the cell differential.

Table 2
Bronchoalveolar lavage cell profiles for normal subjects

Group	N	Volume retrieved (%) ^a	Cells/ μ L BAL fluid	Macrophages (%)	Lymphocytes (%)	Neutrophils (%)	Eosinophils (%)
Never smoked	77	64.0 \pm 1.5	129 \pm 20	85.2 \pm 1.6	11.8 \pm 1.1	1.6 \pm 0.7	0.2 \pm 0.1
Exsmoker	50	61.0 \pm 1.5	139 \pm 11	86.5 \pm 1.4	11.5 \pm 1.2	2.1 \pm 0.5	0.5 \pm 0.2
Smoker	64	59.0 \pm 1.4	418 \pm 45	92.5 \pm 1.0	5.2 \pm 0.9	1.6 \pm 0.2	0.6 \pm 0.1

Multicenter study that used 4 aliquots of 60 ml each for a total of 240 mg instilled saline. (Data from The BAL Cooperative Group Steering Committee. Bronchoalveolar lavage constituents in healthy individuals, idiopathic pulmonary fibrosis, and selected comparison groups. Am Rev Respir Dis 1990;141:S169–202).

^a Percent of total instilled saline volume that was retrieved via aspiration.

Application of bronchoalveolar lavage to the diagnosis of interstitial lung disease

General considerations

Because subacute infection can masquerade as or coexist with noninfectious ILD, minimal examination of BAL should include screening for mycobacterial and fungal infection and the analysis of BAL cellular components. Other testing for infection or malignancy can be performed as indicated clinically and a complete evaluation for infection should be done on BAL fluid if a patient is immunocompromised. Increased numbers of WBC subsets in BAL are suggestive or consistent with certain forms of diffuse infiltrative lung disease and can be used as an aid to diagnosis when combined with clinical presentation (occupational and exposure history, presence of extrapulmonary abnormality, physical examination findings, and pulmonary function testing) and radiographic (especially HRCT) appearance. Certain blood tests also may prove helpful, such as antineutrophil cytoplasmic antibody for Wegener's granulomatosis or antiglomerular basement membrane antibody for Goodpasture's syndrome.

Abnormal cellular profiles in bronchoalveolar lavage and correlation of bronchoalveolar lavage findings with specific interstitial lung diseases

Increased percentages of lymphocytes, neutrophils, or eosinophils indicate a perturbation of airspace cell populations that are likely the result of a pulmonary disorder, but this does not indicate a specific diagnosis per se. Pathologic conditions that predominantly affect airways also alter BAL cell profiles. These entities include bronchitis, bronchiolitis, allergic bronchopulmonary aspergillosis, and asthma. Furthermore, smoking alone can alter cell counts and differentials in BAL fluid; alveolar macrophages (cells/ml) can be increased up to five-fold and show cytoplasmic inclusion bodies resulting from ingestion of tar and other substances, and neutrophil differential counts can be increased, although percent neutrophils on the cell differential may not be increased despite a considerable increase in absolute numbers [35].

Other observations, in addition to differential cell counts, that focus on alveolar macrophages, neutrophils, eosinophils, and lymphocytes, can be made of BAL cell cytopsin preparations. Mast cells usually are present in low numbers in the normal lung, but increases are observed in certain ILDs, although some histologic stains do not stain mast cells adequately [16]. Increased BAL mast cells are observed in

hypersensitivity pneumonitis (HP), IPF, sarcoidosis, asthma, lymphoma, and tuberculosis [36,37]. Plasma cells, usually absent in BAL, also may be detected on cytopsin. Increased plasma cells are reported in HP and may correlate with more intense inflammation [38]. Plasma cells also are identified in BAL in chronic eosinophilic pneumonitis (EP), infections (viral pneumonia, legionellosis, and *P carinii* pneumonia), and lymphoma [38,39]. Macrophages can have a foamy appearance in HP (a nonspecific finding, however); have markedly vacuolated cytoplasm with vacuoles that stain positively for fat in chronic aspiration pneumonitis; show cytoplasmic inclusions consistent with viral infection, such as cytomegalovirus pneumonia; display red blood cell (RBC) fragments and hemosiderin in alveolar hemorrhage; or show ingested asbestos bodies with significant asbestos exposure.

Flow cytometry using antibodies directed against cell surface markers has been applied to ILD and can detect alterations in lymphocyte subset populations. Clinically active pulmonary sarcoidosis characteristically has elevated BAL lymphocytes [40], and an elevated CD4/CD8 T lymphocyte ratio (≥ 3.5) is shown to have a high specificity but low sensitivity for sarcoidosis [41,42]. Many patients do not have elevated CD4/CD8 T lymphocyte ratios [43], however, and the clinical usefulness of performing flow cytometry to obtain T helper lymphocyte subsets when clinical presentation and radiographic imaging support a diagnosis of sarcoidosis is questionable. CD4/CD8 ratios have been observed to be depressed in patients who have other forms of ILD, including HP, drug-induced lung disease, EP, or cryptogenic organizing pneumonia (COP) [44]. Although the CD4/CD8 ratio of BAL T lymphocytes can be determined via flow cytometry, this ratio does not contribute meaningfully to the diagnosis of nonsarcoid ILD, and it may not be elevated even in active sarcoidosis. Langerhans' cell histiocytosis is shown to have increased Langerhans' cells in BAL that can be detected via flow cytometry or via staining cytopsin preparations with anti-CD1a [45,46]. However, the sensitivity of this finding has been stated to be only approximately 50%, because the number of Langerhans' cells in tissue decreases in later stages of disease [47].

Although factors, such as cigarette smoking or the presence of airway disease, can affect BAL cell profiles, differential cell count patterns can, nonetheless, be consistent with a suspected ILD and support its diagnosis (Table 3). When applied to the diagnosis of ILD, increases in the relative percentage on differential cell count for a given WBC cell type (lymphocytes, neutrophils, or eosinophils) has been

Table 3

Bronchoalveolar lavage fluid white blood cell differential profiles and interstitial lung disease

↑ Neutrophils	↑ Eosinophils	↑ Lymphocytes
Infection	Eosinophilic pneumonia	Sarcoidosis
ARDS	Drug-induced ILD	Hypersensitivity pneumonitis
AIP	Churg-Strauss syndrome	Drug-induced ILD
COP	Hypereosinophilic syndrome	Radiation pneumonitis
DIP	Tropical eosinophilia	Chronic beryllium disease
IPF	IPF	Rheumatologic lung disease
Rheumatologic lung disease	Rheumatologic lung disease	Inflammatory gastrointestinal disease
Drug-induced ILD		COP
Hypersensitivity pneumonitis		NSIP
Sarcoidosis		Mycobacterial infection
		Viral pneumonia
		Occupational lung disease
		IPF

termed alveolitis (eg, lymphocytic alveolitis). Frequently, more than one WBC type is increased and termed a mixed cellularity pattern [47]. BAL cell profiles vary among the different forms of IIP (Table 4), but these are nonspecific.

Certain observations, ranging from the gross visual appearance of BAL fluid to extreme increases in cell populations, can be highly suggestive or virtually diagnostic of specific entities in the appropriate clinical setting (Table 5). It is important to examine the freshly retrieved lavage fluid, which may have characteristics that suggest pulmonary hemorrhage, PAP, microlithiasis, or even lipid aspiration as the diagnosis. Bloody BAL fluid (which may range in color from pink or red if acute to orange-brown if subacute), especially if it does not clear or becomes more pronounced as sequential aliquots are aspirated, indicates diffuse alveolar hemorrhage, which has many potential causes [48]. RBCs are present on the cytospin and, if hemorrhage occurs for 24 to 48 hours, alveolar macrophage stains positively for hemosiderin with an iron stain. If freshly retrieved lavage fluid has a cloudy appearance that is milky or light brown and whitish and if flocculent debris settles to the bottom of the container without centrifugation, pulmonary alveolar proteinosis (PAP) is the likely

diagnosis [49]. This sedimented, surfactant-derived lipoproteinaceous material stains positive with periodic acid–Schiff (PAS).

Extreme increases in neutrophils most likely are the result of infection or acute, diffuse lung injury. Although increased eosinophils can be seen in many forms of ILD, their numbers on differential cell count usually do not exceed 10%. An eosinophil differential count greater than or equal to 25% in a patient who has an acute presentation is highly likely to be caused by acute EP, and other forms of eosinophilic lung disease also are associated with high BAL eosinophil numbers [50,51]. BAL lymphocytosis that exceeds 25% is highly likely to be caused by ILD associated with granuloma formation, in particular sarcoidosis and HP. As discussed previously, a CD4/CD8 T lymphocyte ratio greater than or equal to 3.5 increases the specificity for sarcoidosis. When BAL lymphocytosis is correlated with clinical presentation and radiographic findings, however, the determination of lymphocyte subsets, which adds considerable cost to the BAL analysis and may not be available readily in some centers, is of questionable value. Because the BAL CD4/CD8 T lymphocyte ratio tends to increase with advanced age [52], care must be used in interpreting an elevated value in older patients.

Table 4

Bronchoalveolar lavage fluid white blood cell profiles in idiopathic interstitial pneumonia

IIP type	Macrophages (cells/mL)	Neutrophils (%)	Eosinophils (%)	Lymphocytes (%)
IPF	↑	↑/↑↑	↑	NL/↑
NSIP	↑	↑	NL/↑	↑/↑↑
AIP	↑	↑↑	NL	NL/↑
COP	↑	↑	NL/↑	↑/↑↑
DIP	↑↑	NL/↑	NL/↑	NL/↑
RBILD	↑/↑↑	NL/↑	NL	NL
LIP	↑	NL	NL	↑/↑↑

Table 5
Bronchoalveolar lavage observations that are highly suggestive of specific diagnoses

Specimen	Observation	Diagnostic entity suggested
Unprocessed BAL fluid	Progressive increase in RBCs with sequential aliquots	Pulmonary hemorrhage
Unprocessed BAL fluid	Grossly cloudy with milky or light brown appearance; whitish flocculent material settles to the bottom of container when left to stand	Pulmonary alveolar proteinosis
Unprocessed BAL fluid	Cloudy material that clears only with low-speed centrifugation	Microolithiasis
Unprocessed BAL fluid	Oily material that layers out above aqueous phase	Lipid material/lipoid pneumonia
Centrifuged cell pellet	Black appearance; the presence of a black cell pellet after centrifugation suggests that the subject is a smoker or has been	Exposure to significant amounts of carbonaceous material in inhaled air
BAL sediment	Amorphous debris that is positive with PAS stain	Pulmonary alveolar proteinosis
BAL cytospin	Lymphocytosis ($\geq 25\%$)	Sarcoidosis Hypersensitivity pneumonitis Chronic beryllium disease
BAL cytospin	Neutrophilia ($\geq 50\%$)	Bacterial infection AIP
BAL cytospin	Eosinophilia $\geq 25\%$	Eosinophilic pneumonia
BAL cytospin	Hemosiderin positive alveolar macrophage, free RBCs	Pulmonary hemorrhage
BAL flow cytometry	CD4/CD8 lymphocyte ratio ≥ 3.5	Sarcoidosis
BAL flow cytometry	CD1a positive cells $\geq 5\%$	Langerhans' cell histiocytosis

Although BAL is a useful diagnostic adjunct, it is not a stand-alone diagnostic test. It must be interpreted in the context of clinical presentation and radiologic, especially HRCT, findings. Its value increases greatly when it is performed in a standardized fashion, it is examined expertly, and its analysis is combined with clinical data and radiographic imaging (Table 6). When used in this fashion, BAL can be helpful in establishing a specific ILD diagnosis, and it may obviate lung biopsy and the risks of complications that transbronchial lung biopsy or surgical lung biopsy carry (Fig. 1). It can be virtually diagnostic of a specific ILD entity when placed in the context of clinical presentation and radiographic imaging via HRCT. Clinicians should keep in mind, however, that radiographic imaging, including HRCT, may be normal when certain ILDs, such as nonspecific interstitial pneumonitis (NSIP), respiratory bronchiolitis with interstitial lung disease (RBILD), desquamative interstitial pneumonitis (DIP), and HP, are present. If BAL is performed in a symptomatic patient who has normal radiographic imaging, an abnormal cell profile can signal the need for further investigation with lung biopsy.

BAL can be particularly useful when establishing a diagnosis of IPF. A recent multicenter study examined the accuracy of HRCT in establishing a diagnosis of IPF and found that a confident diagnosis of UIP can be made by experienced radiologists in 95% of cases [53]. Lower lung honeycombing and upper lung reticular lines were independent predictors

of UIP on multivariate analysis, and these two factors alone had a positive predictive value of 85%. Although these features on HRCT are highly predictive, the diagnosis of IPF can be made even firmer when BAL is used to rule out other diagnostic entities. An American Thoracic Society–sponsored expert panel recently established criteria for the diagnosis of IPF [54]. This expert panel concluded that transbronchial or surgical lung biopsy is not required to establish the diagnosis of IPF if certain diagnostic criteria are met. These include the presence of four major criteria (exclusions of other known causes of ILD, abnormal pulmonary function studies with evidence of a restrictive ventilatory defect and impaired gas exchange, bibasilar reticular abnormalities with minimal ground glass opacities on HRCT, and transbronchial biopsy or BAL showing no features to support an alternative diagnosis) and three of four minor criteria (age > 50 years, insidious onset of otherwise unexplained dyspnea on exertion, duration of illness ≥ 3 months, and bibasilar inspiratory crackles on chest auscultation).

Present and future applications of bronchoalveolar lavage in interstitial lung disease diagnosis, management, and research

Although many investigators have examined the usefulness of BAL for monitoring the activity of specific ILD, there is no clear role for BAL as a tool

Table 6

Application of bronchoalveolar lavage analysis to the diagnosis of interstitial idiopathic pneumonia and selected other interstitial lung diseases

ILD type	Typical clinical presentation	Typical HRCT pattern	Consistent BAL cell pattern	Circumstances that allow BAL to aid diagnosis
Idiopathic pulmonary fibrosis	Gradual onset of dyspnea in older patient	Diffuse peripheral reticular and honeycomb changes \pm traction bronchiectasis	\uparrow AM, \uparrow Neut \uparrow Eos	Other major and minor criteria for diagnosis of IPF fulfilled
Eosinophilic pneumonia	Diffuse infiltrates on chest x-ray Rapid response to corticosteroids	Bilateral peripheral subpleural airspace consolidation	$\uparrow\uparrow$ Eos	Eos % > 30%
Hypersensitivity pneumonitis	Acute or chronic presentation with exposure history	Acute: bilateral ground glass opacities and poorly defined nodules Chronic: reticular fibrotic pattern \pm honeycomb change, traction bronchiectasis	$\uparrow\uparrow$ Lym, \uparrow Neut “foamy” AM cytoplasm \pm Mast cells \pm Plasma cells	Extreme lymphocytosis Plausible exposure history Exclude infection, hemorrhage
Sarcoidosis	Bilateral hilar lymphadenopathy with normal physical examination; uveitis or erythema nodosum often present	Hilar/mediastinal adenopathy Nodules along bronchovascular bundles in mid/upper lung fields	$\uparrow\uparrow$ Lym, $\pm\uparrow$ Neut	Lymphocytosis with typical clinical presentation and radiographic findings CD4/CD8 ratio \geq 3.5 increases specificity
Nonspecific interstitial pneumonia	Subacute onset of dyspnea	Ground glass opacities or consolidation that involves mainly lower lung zones	\uparrow AM, \uparrow Lym, \uparrow Neut	Typical BAL profile Exclude hemorrhage, infection, malignancy
Scleroderma	Subacute dyspnea on exertion, dysphagia and gastroesophageal reflux; dermal fibrosis and telangiectasias	Reticular \pm ground glass attenuation	\uparrow Lym, \uparrow AM \pm \uparrow Neut, $\pm\uparrow$ Eos	Exclude infection, hemorrhage, malignancy
Cryptogenic organizing pneumonia	Subacute onset of cough, low-grade fever, shortness of breath, fatigue	Patchy, nonsegmental airspace consolidation that may be unilateral and peripheral (can be similar to EP)	\uparrow AM, Lym, Neut \pm \uparrow Eos	Typical BAL profile Exclude hemorrhage, infection, malignancy
Chronic beryllium disease	Exposure history	Hilar adenopathy; nodules along bronchovascular bundles	$\uparrow/\uparrow\uparrow$ Lym	Consistent cell pattern Positive lymphocyte proliferation test
Langerhans' cell histiocytosis of lung	Smoker Subacute onset of dyspnea	Cysts and centrilobular nodules that can cavitate; most prominent in mid to upper lung zones	\uparrow AM \pm \uparrow Neut, \uparrow Eos, or \uparrow Lym	CD1a-positive cells \geq 5%

Pulmonary alveolar proteinosis	Subacute onset of dyspnea	Alveolar filling pattern	Cloudy BAL fluid with milky to light brown appearance; debris settles out without centrifugation	PAS-positive amorphous debris Exclude hemorrhage, infection, malignancy
Diffuse alveolar hemorrhage	Progressive increase in RBCs with sequential BAL aliquots	Patchy or diffuse areas of ground glass attenuation, tend to be in dependent lung zones	Hemosiderin-laden Mac Free RBCs	Exclude infection, malignancy
Drug-induced pneumonitis	Drug ingestion history	Can appear similar to various ILD (UIP, NSIP, DAD, COP, HP, EP)	Variable ↑ Lym, Neut or Eos ± mast cells	Exclude hemorrhage (can be drug-induced), infection, malignancy
Lipoid pneumonia	History of ingestion of mineral, vegetable, or animal oils (?constipation)	Extensive ground glass opacities or consolidation with attenuation values between fat and water	Oily layer on surface of BAL fluid Vacuoles in Mac that stain positive for lipid	Lipid-laden macrophages Exclude infection, hemorrhage
Acute interstitial pneumonitis	Acute onset of dyspnea Diffuse consolidation on CXR	Diffuse, bilateral ground glass attenuation with patchy airspace consolidation	↑↑ Neut	Marked neutrophilia Exclude infection, hemorrhage
Desquamative interstitial pneumonitis	Smoking history	Bilateral ground glass attenuation in lower lung zones	↑↑ Mac	Typical BAL profile Exclusion of hemorrhage, infection, malignancy
RB/ILD	Smoking history	Poorly defined centrilobular nodules, ground glass opacities, and bronchial wall thickening	↑↑ Mac	Exclusion of hemorrhage, infection, malignancy
Lymphocytic interstitial pneumonitis	Reticular or reticulonodular pattern involving mostly lower lung zones Associated with underlying immunologic abnormalities	Bilateral ground glass attenuation and scattered cysts	↑↑ Lym	Elevated lymphocytes Exclusion of hemorrhage, infection, malignancy
Lymphangitic carcinoma	History of malignancy	Smooth or nodular thickening of bronchovascular bundles and interlobular septae or parenchymal nodules	Cytopathologic examination reveals malignant cells	Detection of malignant cells

Abbreviations: AM, alveolar macrophage; Eos, eosinophils; Lym, lymphocytes; Mac, macrophages; Neut, neutrophils.

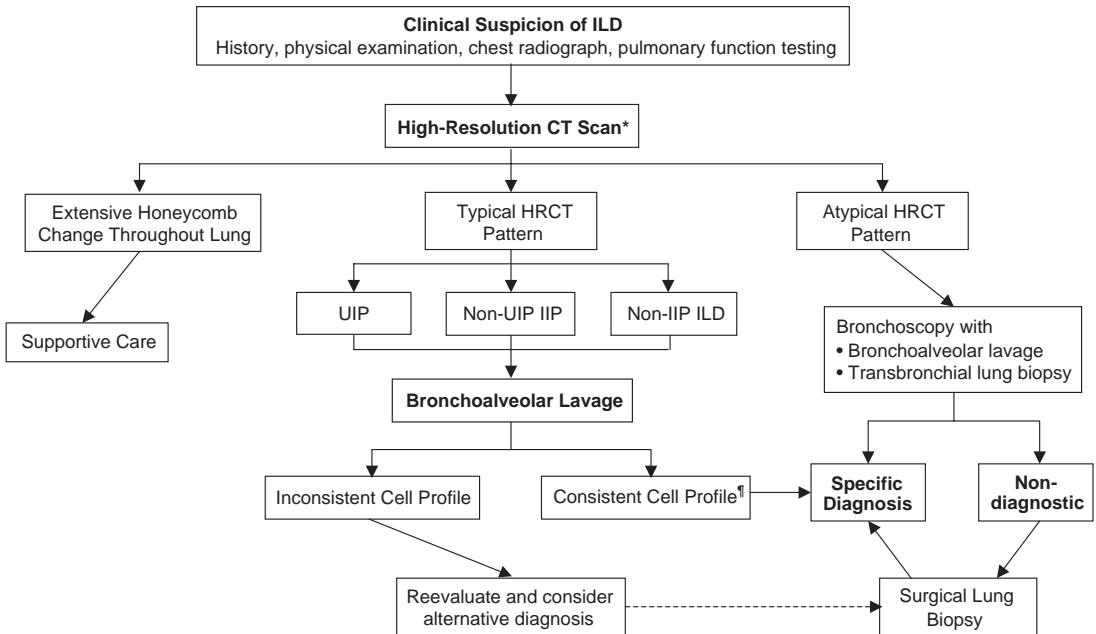


Fig. 1. Use of bronchoalveolar lavage in evaluation of interstitial lung disease. * HRCT may not be necessary in all cases if routine chest radiographic findings are typical/diagnostic of specific ILD (eg, sarcoidosis and fit with other clinical data). † Infection, malignancy, and hemorrhage must be excluded as required by clinical features.

to do so. Some groups have found that BAL cell profiles tend to predict disease severity and likelihood of progression. Lymphocytosis in patients presumed to have IPF is linked to a better prognosis [55–57], whereas eosinophilia is linked to more severe disease and a worse prognosis [57,58]. Many of the patients in these older studies may have had other forms of IIP, however, and a recent investigation shows the coexistence of UIP and NSIP in the lungs of many patients subjected to surgical lung biopsies in multiple geographic areas of the lung [59]. Neutrophilia in sarcoidosis is associated with more severe pulmonary disease that more likely is progressive and less likely to respond to pharmacologic therapy [60], and the degree of increase in BAL neutrophils also is linked to severity and prognosis in HP [36,61] and IPF [62].

Despite the fact that BAL does not seem useful for monitoring disease activity at this time, it can be useful to evaluate complications of ILD. Pulmonary infection, drug reaction, hemorrhage, or an acute exacerbation of the disease may complicate the course of IIP and other ILDs, and BAL may prove helpful in identifying the cause of clinical deterioration. As the understanding of the interplay of inflammatory cells, reactive oxygen species, proteases, cytokines, and chemokines evolves, genomic and proteomic characterization of BAL cells and soluble components may

prove useful in diagnosis, choosing effective therapies, monitoring disease activity, and gauging the effect of therapeutic interventions.

Summary

Bronchoscopy with BAL is a minimally invasive, well-tolerated clinical tool that can be useful in evaluating patients who have diffuse infiltrative lung disease. Although it is infrequently diagnostic by itself, when combined with clinical data and radiographic imaging, a likely diagnosis often can be reached. It is imperative that BAL fluid be examined in a qualified laboratory that has well-established controls and standards that can distinguish normal from abnormal BAL cell profiles readily, and BAL data must be combined with clinical and radiographic data when used as a diagnostic tool to make a specific diagnosis without employing more invasive procedures. BAL is useful particularly to rule out infection or hemorrhage as a cause of diffuse infiltrates, and BAL cell patterns can be useful in reaching a likely diagnosis without performing lung biopsy. The use of BAL is valuable in patients who likely have IPF by numerous clinical and radiographic criteria, because this group seems particularly prone to complications

(prolonged bronchopleural air leaks, loss of lung function as a result of trapped lung in the area of the biopsy, persistent pain, and death) from surgical lung biopsy. When BAL findings are not consistent with a suspected diagnosis, it can indicate need for additional evaluation, including lung biopsy. If the diagnosis of ILD remains unclear despite a combination of BAL with clinical and radiographic findings, a lung biopsy should be considered as the final step to establish a secure diagnosis.

References

- [1] Dacic S, Yousem SA. Histologic classification of idiopathic chronic interstitial pneumonias. *Am J Respir Cell Mol Biol* 2003;29:S5–9.
- [2] Joint Statement of the American Thoracic Society (ATS) and the European Respiratory Society (ERS). ATS/ERS International multidisciplinary consensus classification of the idiopathic interstitial pneumonias. *Am J Respir Crit Care Med* 2002;165:277–304.
- [3] Katzenstein AL, Myers JL. Idiopathic pulmonary fibrosis: clinical relevance of pathologic classification. *Am J Respir Crit Care Med* 1998;157:1301–15.
- [4] Strollo DC. Imaging of the idiopathic interstitial lung diseases: concepts and conundrums. *Am J Respir Cell Mol Biol* 2003;29:S10–8.
- [5] Müller NL, Fraser RS, Lee KS, Johkoh T. Diseases of the lung. Philadelphia: Lippincott Williams & Wilkins; 2003.
- [6] Collins J. CT signs and patterns of lung disease. *Radiology Clin North Am* 2001;39:1115–35.
- [7] Stitt HL. Bronchial aspiration and irrigation with a hypertonic saline solution. *J Med* 1927;5:112–7.
- [8] Stitt HL. Bronchial lavage. *Bull St Louis Med Soc* 1932;26:246–9.
- [9] Ramirez RJ, Schultz RB, Dutton RE. Pulmonary alveolar proteinosis. A new technique and rationale for treatment. *Arch Intern Med* 1963;112:419–31.
- [10] Kylstra JA, Rausch DC, Hall KD, Spock A. Volume controlled lung lavage in the treatment of asthma, bronchiectasis and mucoviscidosis. *Am Rev Respir Dis* 1971;103:651–65.
- [11] Myrvik QN, Leake ES, Fariss B. Studies of pulmonary alveolar macrophages from the normal rabbit: a technique to procure them in a high state of purity. *J Immunol* 1961;86:128–32.
- [12] Collins FM, Mackaness GB. Delayed hypersensitivity and arthus reactivity in relation to host resistance in Salmonella infected mice. *J Immunol* 1968;101:830–45.
- [13] Reynolds HY, Thompson RE. Pulmonary host defenses. I. Analysis of protein and lipids in bronchial secretions and antibody responses after vaccination with *Pseudomonas aeruginosa*. *J Immunol* 1973;111:358–68.
- [14] Reynolds HY, Thompson RE. Pulmonary host defenses. II. Interaction of respiratory antibodies with *Pseudomonas aeruginosa* and alveolar macrophages. *J Immunol* 1974;111:369–80.
- [15] Reynolds HY, Newball HH. Analysis of proteins and respiratory cells obtained from human lungs by bronchial lavage. *J Lab Clin Med* 1974;84:559–73.
- [16] Klech H, Pohl W. Technical recommendations and guidelines for bronchoalveolar lavage (BAL). *Eur Respir J* 1989;2:561–85.
- [17] Haslam PL, Baughman RP. ERS task force report on measurement of acellular components in BAL. *Eur Resp Rev* 1999;9:25–7.
- [18] The BAL Cooperative Group Steering Committee. Bronchoalveolar lavage constituents in healthy individuals, idiopathic pulmonary fibrosis, and selected comparison groups. *Am Rev Respir Dis* 1990;141: S169–202.
- [19] Ahmad M, Livingston DR, Golish JA, Mehta AC, Wiedemann HP. The safety of outpatient transbronchial biopsy. *Chest* 1986;90:403–5.
- [20] Simpson FG, Arnold AG, Purvis A, Belfield PW, Muers MF, Cooke NJ. Postal survey of bronchoscopic practice by physicians in the United Kingdom. *Thorax* 1986;41:311–7.
- [21] Kramer MR, Berkman N, Mintz B, Godfrey S, Saute M, Amir G. The role of open lung biopsy in the management and outcome of patients with diffuse lung disease. *Ann Thorac Surg* 1998;65:198–202.
- [22] Utz JP, Ryu JH, Douglas WW, Hartman TE, Tazelaar HD, Myers JL, et al. High short-term mortality following lung biopsy for usual interstitial pneumonia. *Eur Respir J* 2001;17:175–9.
- [23] Klech H, Hutter C. Side-effects and safety of BAL. *Eur Respir J* 1990;3:939–40, 961–9.
- [24] Dhillon DP, Haslam PL, Townsend PJ, Primett Z, Collins JV, Turner-Warwick M. Bronchoalveolar lavage in patients with interstitial lung diseases: side effects and factors affecting fluid recovery. *Eur J Respir Dis* 1986;68:342–50.
- [25] Rankin JA, Naegel GP, Reynolds HY. Use of a central laboratory for analysis of bronchoalveolar lavage fluid. *Am Rev Respir Dis* 1986;133:186–90.
- [26] Dohn MN, Baughman RP. Effect of changing instilled volume for bronchoalveolar lavage in patients with interstitial lung disease. *Am Rev Respir Dis* 1985;132: 390–2.
- [27] Helmers RA, Dayton CS, Floerchinger C, Hunninghake GW. Bronchoalveolar lavage in interstitial lung disease: effect of volume of fluid infused. *J Appl Physiol* 1989;67:1443–6.
- [28] Martin TR, Raghu G, Maunder RJ, Springmeyer SC. The effects of chronic bronchitis and chronic air-flow obstruction on lung cell populations recovered by bronchoalveolar lavage. *Am Rev Respir Dis* 1985; 132:254–60.
- [29] Bjermer L, Rust M, Heurlin N, Rennard S, Klech H. The clinical use of bronchoalveolar lavage in patients with pulmonary infections. *Eur Respir Rev* 1992; 2(8R):106–13.

- [30] De Brauwier EIGB, Drent M, Mulder PGH, Bruggeman CA, Wagenaar SS, Jacobs JA. Differential cell analysis of cytocentrifuged bronchoalveolar lavage fluid samples affected by the area counted. *Anal Quant Cytol Histol* 2000;22:143–9.
- [31] Costabel U, Bross KJ, Natthys H. Diagnosis by bronchoalveolar lavage of cause of pulmonary infiltrates in haematological malignancies. *BMJ* 1985;290:1041.
- [32] De Gracia J, Bravo C, Miravittles M, Tallada N, Orriols R, Bellmunt J, et al. Diagnostic value of bronchoalveolar lavage in peripheral lung cancer. *Am Rev Respir Dis* 1993;147:649–52.
- [33] Semenzato G, Poletti V. Bronchoalveolar lavage in lung cancer. *Respiration (Herrlisheim)* 1992;59(Suppl 1):44–6.
- [34] Meyer KC, Rosenthal NS, Soergel P, Peterson K. Neutrophils and low-grade inflammation in the seemingly normal aging human lung. *Mech Ageing Dev* 1998;104:169–81.
- [35] Costabel U, Guzman J. Effect of smoking on bronchoalveolar lavage constituents. *Eur Respir J* 1992;5:776–9.
- [36] Drent M, van Velzen Blad H, Diamant M, Wagenaar SS, Hoogsteden HC, van den Bosch JM. Bronchoalveolar lavage in extrinsic allergic alveolitis: effect of time elapsed since antigen exposure. *Eur Respir J* 1993;6:1276–81.
- [37] Drent M, Wagenaar S, Mulder PGH, van Velzen-Blad H, Diamant M, van den Bosch JM. Bronchoalveolar lavage fluid profiles in sarcoidosis, tuberculosis, and non-Hodgkin's and Hodgkin's disease. An evaluation of differences. *Chest* 1994;105:514–9.
- [38] Drent M, van Velzen Blad H, Diamant M, Wagenaar SS, Donekerwolek-Bogaert M, van den Bosch JM. Differential diagnostic value of plasma cells in bronchoalveolar lavage fluid. *Chest* 1993;103:1720–4.
- [39] Jacobs JA, Dieleman MM, Cornelissen E, Groen EA, Wagenaar SS, Drent M. Bronchoalveolar lavage fluid cytology in patients with *Pneumocystis carinii* pneumonia. *Acta Cytol* 2001;45:317–26.
- [40] Hunninghake GW, Crystal RG. Pulmonary sarcoidosis: a disorder mediated by excess helper T-lymphocyte activity at sites of disease activity. *N Engl J Med* 1981;305:429–32.
- [41] Winterbauer RH, Lammert J, Selland M, Wu R, Corley D, Springmeyer SC. Bronchoalveolar lavage cell populations in the diagnosis of sarcoidosis. *Chest* 1993;104:252–61.
- [42] Costabel U, Zaiss AW, Guzman J. Sensitivity and specificity of BAL findings in sarcoidosis. *Sarcoidosis* 1992;9(Suppl 1):211–4.
- [43] Kantrow SP, Meyer KC, Kidd P, Raghu G. The CD4/CD8 ratio in BAL fluid is highly variable in sarcoidosis. *Eur Respir J* 1997;10:2716–21.
- [44] Drent M, Jacobs JA. Bronchoalveolar lavage. In: Baughman RP, Du Bois RM, Lynch III JP, Wells AU, editors. *Diffuse lung disease: a practical approach*. New York: Oxford University Press; 2004. p. 56–64.
- [45] Chollet S, Soler P, Doumovo P, Richard MS, Ferrans VJ, Basset F. Diagnosis of pulmonary histiocytosis X by immunodetection of Langerhans cells in bronchoalveolar lavage fluid. *Am J Pathol* 1984;115:225–32.
- [46] Auerswald U, Barth J, Magnussen H. Value of CD1 positive cells in bronchoalveolar lavage fluid for the diagnosis of pulmonary histiocytosis X. *Lung* 1990;169:305–9.
- [47] Costabel U, Guzman J. Bronchoalveolar lavage. In: Schwartz MI, King Jr TE, editors. *Interstitial lung disease*. Hamilton (Ontario, Canada): BC Decker; 2003. p. 114–33.
- [48] Fontenot AP, Schwarz MI. Diffuse alveolar hemorrhage. In: Schwartz MI, King Jr TE, editors. *Interstitial lung disease*. Hamilton (Ontario, Canada): BC Decker; 2003. p. 632–56.
- [49] Martin RJ, Coalson JJ, Rogers RM, Horton FO, Manous LE. Pulmonary alveolar proteinosis: the diagnosis by segmental lavage. *Am Rev Respir Dis* 1980;121:819–25.
- [50] Pope-Harman AL, Davis WB, Allen ED, Christoforidis AJ, Allen JN. Acute eosinophilic pneumonia. A summary of 15 cases and review of the literature. *Medicine (Baltimore)* 1996;75:334–42.
- [51] Allen JN, Davis WB. Eosinophilic lung diseases. *Am J Respir Crit Care Med* 1994;150:1423–38.
- [52] Meyer KC, Soergel P. Bronchoalveolar lymphocyte phenotypes change in the normal aging human lung. *Thorax* 1999;54:697–700.
- [53] Hunninghake GW, Lynch DA, Galvin JR, Gross BH, Schwartz DA, King Jr TE, et al. Radiologic findings are strongly associated with a pathologic diagnosis of usual interstitial pneumonia. *Chest* 2003;124:1215–23.
- [54] Joint Statement of the American Thoracic Society (ATS) and the European Respiratory Society (ERS). Idiopathic pulmonary fibrosis: diagnosis and treatment: international consensus statement. *Am J Respir Crit Care Med* 2000;161:646–64.
- [55] Haslam PL, Turton CWG, Lukoszek A, Salisbury AJ, Dewar A, Collins JV, et al. Bronchoalveolar lavage fluid cell counts in cryptogenic fibrosing alveolitis and their relation to therapy. *Thorax* 1980;35:328–39.
- [56] Turner-Warwick M, Haslam PL. The value of serial bronchoalveolar lavages in assessing the clinical progress of patients with cryptogenic fibrosing alveolitis. *Am Rev Respir Dis* 1987;135:26–34.
- [57] Watters LC, Schwarz MI, Cherniack RM, Waldron JA, Dunn TL, Stanford RE. Idiopathic pulmonary fibrosis: pretreatment bronchoalveolar lavage cellular constituents and their relationships with lung histopathology and clinical response to therapy. *Am Rev Respir Dis* 1987;135:696–704.
- [58] Peterson WMW, Monick M, Hunninghake GW. Prognostic role of eosinophils in pulmonary fibrosis. *Chest* 1987;92:51–6.
- [59] Flaherty KR, Travis WD, Colby TV, Toews GB, Kazerooni EA, Gross BH, et al. Histopathologic variability in usual and nonspecific interstitial pneumonias. *Am J Respir Crit Care Med* 2001;164:1722–7.

- [60] Drent M, Macobs JA, de Vries J, Lamers RJ, Liem IH, Wouters EF. Does the cellular bronchoalveolar lavage fluid profile reflect the severity of sarcoidosis? *Eur Respir J* 1999;13:1338–44.
- [61] Haslam PL, Dewar A, Butchers P, Primett ZS, Newman-Taylor A, Turner-Warwick M. Mast cells, atypical lymphocytes, and neutrophils in bronchoalveolar lavage in extrinsic allergic alveolitis. Comparison with other interstitial lung diseases. *Am Rev Respir Dis* 1987;135:35–47.
- [62] Lynch JPD, Standiford TJ, Rolfe MW, Kunkel SL, Strieter RM. Neutrophilic alveolitis in idiopathic pulmonary fibrosis. The role of interleukin-8. *Am Rev Respir Dis* 1992;145:1433–9.