

# Chapter 4

## **Azathioprine induced pneumonitis in a patient with ulcerative colitis**

## Abstract

Immunomodulator therapy with the thiopurine analogues azathioprine (AZA) or 6-mercaptopurine (6-MP) is commonly prescribed for maintenance of remission in inflammatory bowel disease (IBD).

Ten to twenty-five percent of patients have to withdraw from AZA or 6-MP due to adverse events that are partly explained by the relative activity of the drug metabolizing enzymes. Most of the potential major adverse events (myelosuppression, hepatotoxicity and pancreatitis) are well known. Pulmonary toxicity is rare but severe and may lead to respiratory insufficiency and even death. We describe a case of a young woman with ulcerative colitis (UC) who developed respiratory symptoms and fever combined with nodular densities and ground glass areas in both lungs on CT scan. An infection was ruled out and the diagnosis azathioprine induced pneumonitis was made. The drug was stopped and within one week her fever and respiratory symptoms resolved. Clinicians should be alert to this serious adverse event when treating patients with thiopurines.

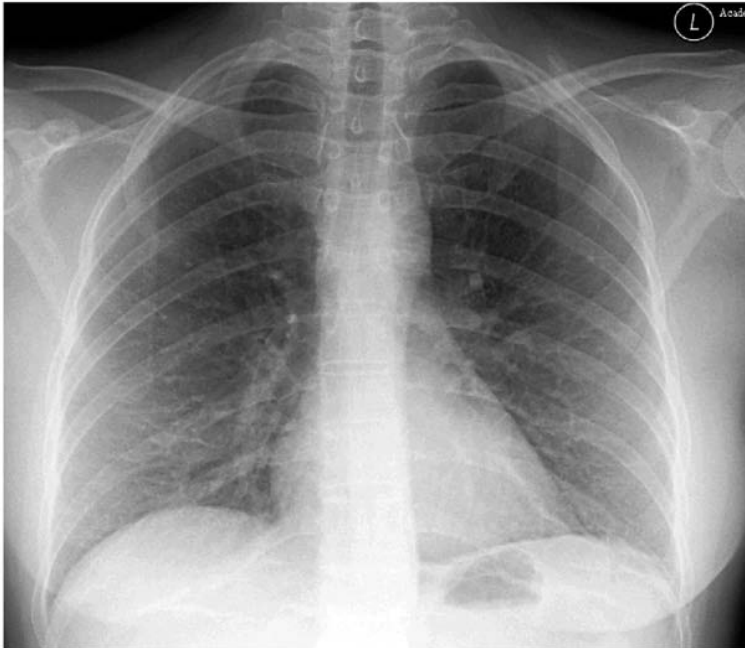
## Introduction

The thiopurines azathioprine (AZA) and 6-mercaptopurine (6-MP) are frequently used as immunomodulating drugs in inflammatory bowel disease (IBD) patients. In both Crohn's disease (CD) and ulcerative colitis (UC) thiopurines have proven to be efficacious as maintenance therapy and are steroid sparing, nevertheless up to 20% of patients have to discontinue therapy because of adverse events<sup>1-3</sup>. These adverse events can be divided in two categories: dose dependent reactions which are the direct result of altered activity of one of the drug metabolizing enzymes thiopurine-S-methyltransferase (TPMT), xanthine oxidase (XO) or inosine triphosphate pyrophosphatase (ITPase) and subsequently formation of an excess of potentially toxic metabolites and secondly dose independent allergic or hypersensitivity reactions<sup>4</sup>. The first category side effects are well known and include myelosuppression, hepatotoxicity and general symptoms like malaise and nausea. The dose independent idiosyncratic reactions are less frequent and include symptoms like fever, rash, arthralgias and pancreatitis<sup>5</sup>. Severe pulmonary toxicity is rare. We describe a case of a young woman with ulcerative colitis and an allergic pneumonitis on AZA and review the current literature.

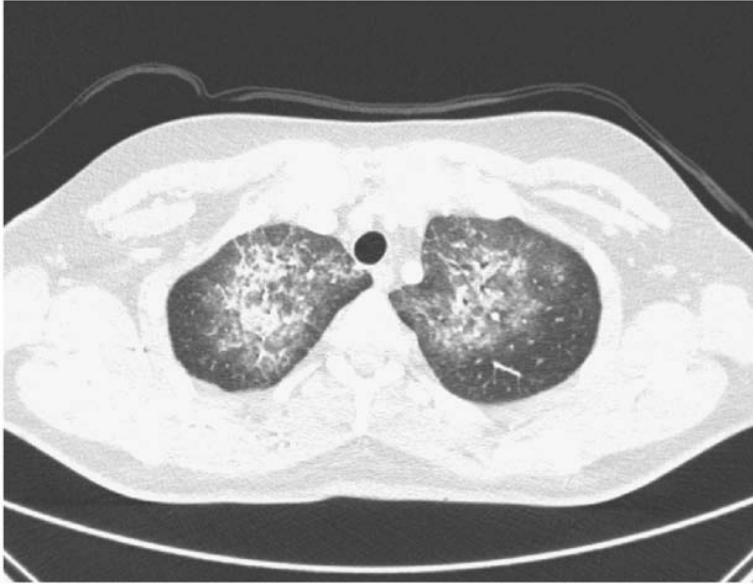
## Case report

Our patient is a 40-year-old female known with left-sided ulcerative colitis since 2007. Her other medical history is unremarkable. She was initially treated with mesalazine/beclomethason dipropionate enemas and oral mesalazine 3 g daily. Because of a refractory disease with frequent stools and rectal blood loss, sigmoidoscopy was performed and showed a distal (0–25 cm) ulcerative colitis Mayo score 3. Biopsies showed no CMV and infectious colitis was ruled out with a stool culture. A course of oral corticosteroids (starting dose 40 mg, gradually tapered) was started combined with azathioprine (AZA) (2 mg/kg) and mesalazine was discontinued at that point. Monitoring of complete blood count, liver enzymes and lipase was performed according to protocol one week, two weeks and one month after the start of thiopurine therapy and no abnormal values were found. Five weeks after starting prednisone (current dose 10 mg) and AZA she developed fever, dry cough and shortness of breath. At that time she had no abdominal complaints. An initial course of antibiotics did not improve her symptoms. Physical examination revealed a tachycardia but lung sounds were clear, no skin rash was present. Laboratory results showed a decreased white blood cell count ( $2.4 \times 10^9/l$ ) and hemoglobin concentration (5.4 mmol/l). Platelets were normal. C-reactive protein was 103 mg/l (normal value <10 mg/l). Liver enzymes including aminotransferases were increased (AST 60 U/l; normal value <30 U/l, ALT 64 U/l; normal value <35 U/l). TPMT activity in erythrocytes was decreased: 0.28  $\mu\text{mol}/\text{mmol Hb}/\text{h}$  (reference  $0.43 \pm 0.07$ ). DNA-analysis revealed \*1/\*3C TPMT genotype compatible with intermediate TPMT enzyme activity.

Chest X-ray was normal, but an additional CT-scan revealed multiple nodular densities surrounded by ground glass areas in the apical part of both lungs (Figures 4.1 and 4.2). Subsequently a bronchoscopy with bronchoalveolar lavage was performed. The lavage fluid mainly contained lymphocytes and macrophages and all cultures were negative. Specific tests for viruses, fungi, mycobacteria, *Pneumocystis jiroveci*, *Legionella pneumophila* and rickettsiae were also negative and the diagnosis azathioprine-induced pneumonitis was made. AZA was discontinued three days after onset of fever, prednisone was continued in the current dose of 10 mg and tapered and stopped two weeks later. Within four days after admission to the hospital her fever resolved and respiratory symptoms decreased. Leukocyte count returned to normal within two weeks after discontinuation of AZA. She was not treated with intensified prednisone dosage because no hypoxemia was present. One month later she had recovered completely. Mesalazine was restarted as maintenance therapy for the ulcerative colitis. So far no flares have occurred.



**Figure 4.1** Normal chest radiogram.



**Figure 4.2** High resolution CT scan of chest shows confluent.

## Discussion

We report a case of lung toxicity of AZA in a young patient with UC. This side effect is only incidentally reported in literature but can be severe and even lethal. Our patient developed pulmonary symptoms five weeks after the initiation of AZA. Cessation of the thiopurine resulted in rapid improvement of symptoms. Most cases of pulmonary toxicity attributed to AZA were reported in patients after renal allograft transplantation. The largest series was published in 1984 by Bedrossian et al. regarding seven patients with diffuse alveolar damage and usual interstitial pneumonitis taking AZA after kidney transplantation. Four of the seven patients died of adult respiratory distress syndrome<sup>6,7</sup>. Diffuse alveolar hemorrhage due to severe AZA induced myelosuppression was also described<sup>8</sup>. During the last 35 years seven cases of pulmonary toxicity in IBD patients on immunosuppressive therapy with thiopurines have been described (Table 4.1).

The majority of the patients were treated with AZA, only one paper reports the use of 6-MP. Most of the IBD patients with reported lung toxicity were men (86%; 6 M/1 F). Four patients had CD and three patients were diagnosed with UC. Median age was 41 years (range 18–71). Interestingly the white blood cell count was normal or increased in most cases in contrast to our patient who had a leucopenia due to decreased activity of the TPMT enzyme.

Patients with \*1/\*3C *TPMT* genotype inherit one wild type allele and one mutant allele and have intermediate *TPMT* enzyme activity. The risk of acute or delayed myelosuppression (mainly leucopenia) is increased in these patients and warrant strict blood monitoring and possibly dose adjustment of AZA or 6MP.

**Table 4.1** Cases pulmonary toxicity thiopurines in IBD patients.

Author <sup>(ref)</sup>	UC / CD	Age / sex	AZA / 6MP	Dosage	Interval between start therapy and symptoms	Concomitant medication	WBC (x10 <sup>9</sup> /l)
Rubin <sup>13</sup>	CD	20/M	AZA		4 months	Prednisone	
Krowka <sup>14</sup>	CD	35/M	AZA	125 mg	4 months	Prednisone	15,5
Nagy <sup>9</sup>	UC	41/M	AZA	150 mg (1,8 mg/kg)	10 year	Olsalazine, methylprednisolone	4,4
Ananthakrishnan <sup>10</sup>	CD	66/M	First AZA, later 6MP	50 mg	4 weeks	Prednisone, Infliximab 3 months before	8,4
	CD	71/M	AZA	100 mg	4 weeks	Prednisone, infliximab, >20 cyclosporine	
	UC	43/F	AZA	100 mg	3 weeks	Prednisone	
Katsenos <sup>12</sup>	UC	18/M	AZA	100 mg		Mesalazine	

The time interval between initiation of thiopurine therapy and the beginning of pulmonary symptoms and fever is in most cases one to four months but can even be years. Nagy et al. published in 2007 a case of a 41-year old man with UC who developed severe pulmonary disease related to AZA ten years after starting treatment. Despite discontinuation of AZA the interstitial inflammation was progressive and resulted in acute respiratory distress syndrome (ARDS)<sup>9</sup>. The largest case series of pulmonary toxicity during AZA/6-MP treatment in IBD patients was published in 2007. Three patients with IBD, two with CD and one with UC were described. They all had a longstanding history of IBD (4–12 years). In all patients AZA was started because of a flare under mesalamine maintenance or inability to taper corticosteroids. The starting dose was 50 mg in one patient and 100 mg in the two other patients. Pulmonary side effects started within four weeks after initiation of thiopurine therapy and symptoms were similar to the symptoms in our patient. Two patients required mechanical ventilation because of progressive hypoxemia despite additional treatment with intravenous corticosteroids. Rechallenge with 6-MP after initial allergic reaction to AZA led to severe pulmonary and systemic disease requiring mechanical ventilation in a 66-year old man with CD. In two patients open lung biopsy was performed revealing usual interstitial pneumonitis with diffuse alveolar damage and bronchiolitis obliterans organizing pneumonia (BOOP)<sup>10</sup>. Our patient was using mesalazine before starting treatment with AZA. The possibility of mesalazine hypersensitivity in our patient is

unlikely since the drug was discontinued more than one month before the onset of the respiratory complaints and reintroduced without any problems after discontinuation of AZA. A wide variety of pulmonary manifestations besides (opportunistic) infections and drug-induced reactions is described in IBD patients. Pulmonary vasculitis, chronic bronchitis and bronchiolitis, fibrosing alveolitis or eosinophilic pneumonia should be considered as differential diagnosis in IBD patients presenting with dyspnea, cough or fever<sup>11</sup>. The acute onset of complaints, quick recovery after discontinuation of AZA and no infectious etiology found, clearly favours AZA-induced pneumonitis in our patient. Our case highlights a potentially life-threatening side effect of thiopurine therapy. Interestingly a dose dependent drug reaction (myelosuppression) and an idiosyncratic reaction (pneumonitis) occurred simultaneously in this same patient. This has not been reported before. Clinicians should be aware of the possibility of a severe pulmonary adverse reaction besides opportunistic infections when patients present with pulmonary symptoms, fever and abnormalities on chest X-ray or CT-scan. A careful evaluation for potential infectious etiologies including bronchoscopy and bronchoalveolar lavage should first be performed. AZA or 6-MP should be discontinued immediately when lung toxicity is suspected. Clinical improvement is observed in most cases after cessation of thiopurine therapy. Corticosteroids should be considered as additional treatment in severe cases especially if hypoxemia is present.

## References

1. Adler DJ, Korelitz BI. The therapeutic efficacy of 6-mercaptopurine in refractory ulcerative colitis. *Am J Gastroenterol* 1990;85:717-22.
2. Sandborn WJ. A review of immune modifier therapy for inflammatory bowel disease: azathioprine, 6-mercaptopurine, cyclosporine, and methotrexate. *Am J Gastroenterol* 1996;91:423-33.
3. Pearson DC, May GR, Fick GH, Sutherland LR. Azathioprine and 6-mercaptopurine in Crohn's disease. A meta-analysis. *Ann Intern Med* 1995;123:132-42.
4. Derijks LJ, Gilissen LP, Hooymans PM, Hommes DW. Review article: thiopurines in inflammatory bowel disease. *Aliment Pharmacol Ther* 2006;24:715-29.
5. de Jong DJ, Derijks LJ, Naber AH, Hooymans PM, Mulder CJ. Safety of thiopurines in the treatment of inflammatory bowel disease. *Scand J Gastroenterol Suppl* 2003;239:69-72.
6. Bedrossian CW, Sussman J, Conklin RH, Kahan B. Azathioprine-associated interstitial pneumonitis. *Am J Clin Pathol* 1984;82:148-54.
7. Carmichael DJ, Hamilton DV, Evans DB, Stovini PG, Calne RY. Interstitial pneumonitis secondary to azathioprine in a renal transplant patient. *Thorax* 1983;38:951-2.
8. Perri D, Cole DE, Friedman O, Piliotis E, Mintz S, Adhikari NK. Azathioprine and diffuse alveolar haemorrhage: the pharmacogenetics of thiopurine methyltransferase. *Eur Respir J* 2007;30:1014-7.
9. Nagy F, Molnar T, Makula E, Kiss I, Milassin P, Zollei E, Tiszlavicz L, Lonovics J. A case of interstitial pneumonitis in a patient with ulcerative colitis treated with azathioprine. *World J Gastroenterol* 2007;13:316-9.
10. Ananthakrishnan A, Atilla T, Otterson M, Lipchik R, Massey B, Komorowski R, Binion D. Severe pulmonary toxicity after azathioprine/ 6-mercaptopurine initiation for the treatment of inflammatory bowel disease. *J Clin Gastroenterol* 2007;41:682-8.
11. Storch I, Sachar D, Katz S. Pulmonary manifestations of inflammatory bowel disease. *Inflamm Bowel Dis* 2003;9:104-15.
12. Katsenos S, Psathakis K, Kokkonouzis I, Panagou P, Tsintiris K, Bouros D. Drug- induced pulmonary toxicity in a patient treated with mesalazine and azathioprine for ulcerative colitis. *Acta Gastroenterol Belg* 2007;70:290-2.
13. Rubin G, Baume P, Vandenberg R. Azathioprine and acute restrictive lung disease. *Aust N Z Med* 1972;2:272-4.
14. Krowka MJ, Breuer RI, Kehoe TJ. Azathioprine-associated pulmonary dysfunction. *Chest* 1983;83:696-8.